

Sounding Out COVID-19 Pneumonitis by Lung POCUS

The Role of Lung POCUS in COVID-19

A Case Study by:
Dr. Nick Mani, MD

“My Butterfly iQ+ is an invaluable and ideal diagnostic device in triaging and assessing patients with suspected COVID-19. It has replaced my stethoscope. Period.”

Introduction

Severe Acute Respiratory Syndrome CoronaVirus 2 (SARS-CoV-2) is the underlying cause of Coronavirus disease 2019 (COVID-19). The World Health Organisation (WHO) declared it a global pandemic in March 2020¹. Since then it has caused significant morbidity and mortality, and continues to do so in the wake of its second surge.

COVID-19 is a syndrome, with viral pneumonitis as one of the most commonly observed manifestations. The most frequent presenting complaints including worsening shortness of breath and cough. It can progress to respiratory failure, requiring supplemental oxygen therapy and other supportive treatment sometimes in critical care settings².

Lung Computed Tomography (CT) has a high accuracy for detecting features of COVID-19 pneumonitis, mainly ground glass changes and bilateral infiltrates. These findings combined with a positive Real Time Polymerase Chain Reaction (RT-PCR) confirm the diagnosis³. However due to many reasons (cost, access, decontamination requirements), Lung CT is not the most ideal initial imaging modality in a global pandemic. On the other hand, Chest XR (CXR) has unacceptably low accuracy for detecting abnormalities, particularly in the early stages of the disease process⁴⁻⁶.

Lung Point-Of-Care Ultra-Sound (POCUS) has emerged as the ideal imaging modality, particularly in frontline specialties such as emergency medicine, for triage and assessment of patients with suspected COVID-19 pneumonitis. The features have now been widely observed and described⁷, in keeping with the general principles of Lung Ultrasound (LUS) as described by the likes of Lichtenstein et al in 2008.⁸ The aim of this case study is to describe the utilisation and role of Lung US in COVID-19 Pneumonitis triage and assessment.

Case History

In October 2020, a gentleman in his 20's presented to the emergency room by ambulance with progressively worsening shortness of breath, cough and fever over the last several days. The patient was otherwise fit and well, with no significant medical history.

He was in significant respiratory distress with oxygen saturation of 80% on room air, respiratory rate 36/min, febrile, but otherwise hemodynamically stable. The arterial blood gas demonstrated severe type 1 respiratory failure, and the patient required 60% supplementary oxygen via Venturi mask to maintain oxygen saturation of above 94%. The portable CXR was inconclusive, and ECG was normal.

The initial differential diagnoses included COVID-19 pneumonitis, bacterial pneumonia, pneumothorax, and pulmonary embolism.

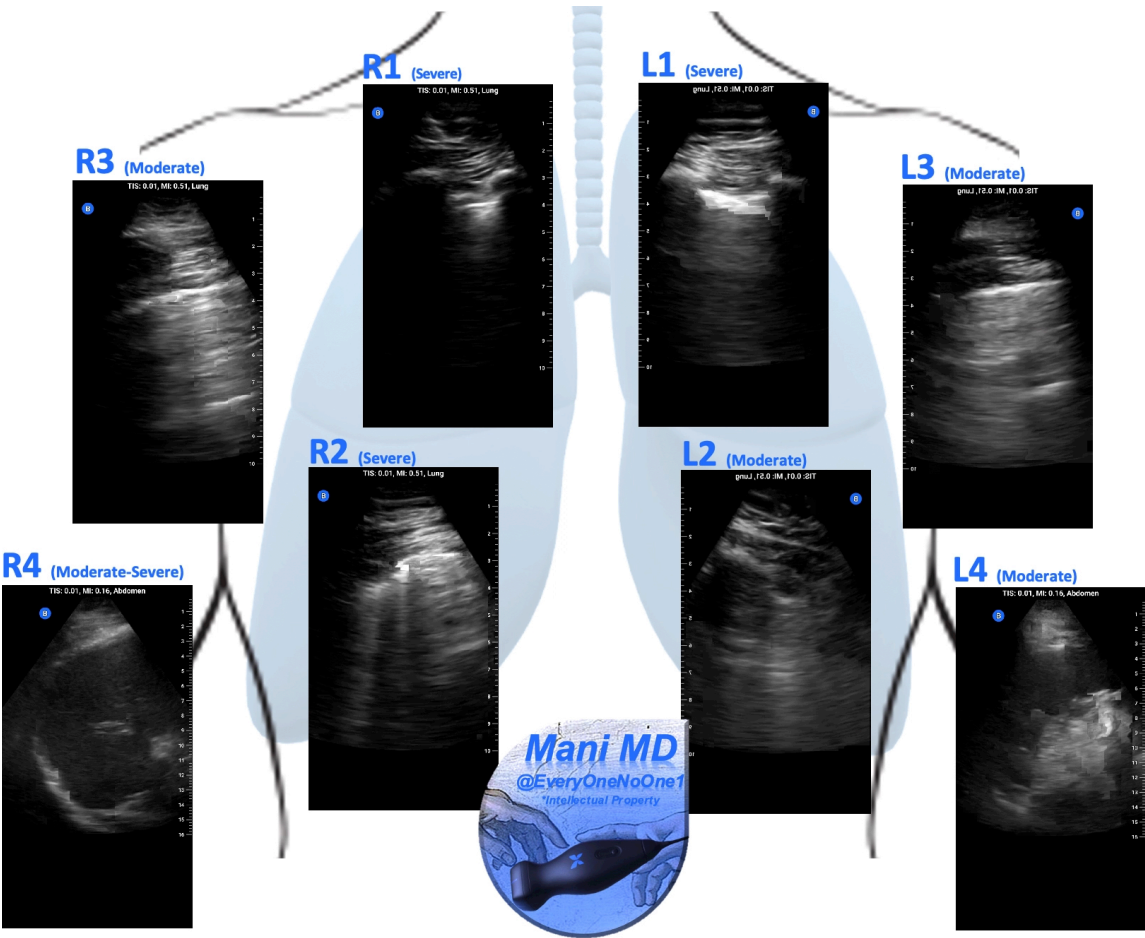
8-Zone LUS was performed at bedside using the Butterfly iQ+ device, demonstrating abnormalities in both lungs and all zones, in keeping with severe viral pneumonitis (VideoClip). The focused echo and proximal DVT examination were normal.

The above Lung POCUS findings significantly rapidly narrowed the differential diagnosis to COVID-19 Pneumonitis and/or Bacterial Pneumonia as the most likely cause, with no need for lung CT scan. RT-PCR swabs were obtained, antibiotics and dexamethasone were administered, and the patient was admitted to a high dependency unit for ongoing care and assessment.

Imaging and Outcome

After preparing the medial upper arm with chlorhexidine and placing a tourniquet, the patient’s right basilic vein was identified. A 2.5-inch 18g needle was guided easily into the vein on the first attempt. After threading the catheter into the vein, the ultrasound was used to confirm catheter placement. The catheter was then secured. The patient expressed surprise at the rapidity and ease of the procedure compared to previous hospitalizations.

Ultimately, the patient was SARS-CoV-2 PCR negative and was admitted to the hospital for further neurological testing. After a thorough inpatient evaluation, the workup revealed no changes from previous evaluations, his symptoms resolved, and the patient was discharged with his outpatient medication regimen and instructions to follow with his primary care providers. The IV remained in place throughout his entire three-day hospitalization.



8-Zone LUS Performed by the Butterfly iQ+

R/L- Right/Left Zone, 1- Anterior Superior Zone, 2- Anterior Inferior Zone, 3- Lateral Superior Zone, 4- Lateral Inferior Zone (Posterior Zones were not performed due to the clinical severity of the patient and the findings in the other zones) All zones demonstrate various combinations of loss of A-lines, B-lines, pleural abnormalities. In R1 and R2, subpleural consolidation and confluent/heterogenous B-lines are present, with other findings being more obvious.

Conclusion

Utilisation of LUS has a growing evidence-based and is quickly becoming an established modality for the assessment of patients presenting with shortness of breath and respiratory failure.⁷ Furthermore, it had shown promise as a diagnostic tool in previous viral epidemics, such as the 2009 influenza (H1N1) epidemic and the 2013 avian influenza (H7N9).^{9–11}

In the COVID-19 global pandemic, lung POCUS has proven itself invaluable once again. The LUS findings in COVID-19 include loss of A-lines, heterogenous and confluent B-lines, pleural line abnormalities, and subpleural consolidation, with pleural effusion being a rare finding.¹² These findings seem to be more detectable in the posterior-lateral aspect of the lung, at least in the early stages.¹² There have been various invalidated scoring systems, incorporating lung US alongside other information, for triage and assessment purposes.⁷ In the face of COVID-19 global pandemic surges, the upskilling of as many as health care professionals as possible to perform basic LUS with the appropriate devices such as the Butterfly iQ+ is both appropriate and useful.^{13, 14}

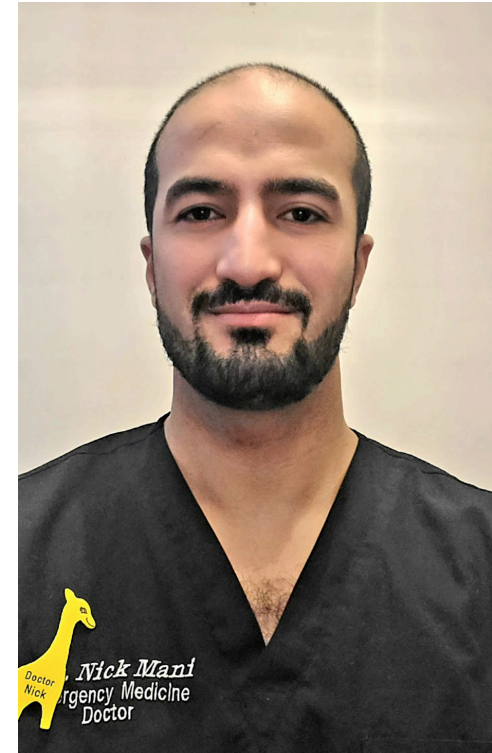The form factor and quality of the Butterfly iQ+ make it an ideal device to perform Lung POCUS for the triage and assessment of patients suspected of COVID-19 pneumonitis. It has replaced my stethoscope for the foreseeable future and has enhanced my clinical practice significantly, ultimately improving patient care, safety, and flow.

References

1. World Health Organization. Coronavirus disease (COVID-19) dashboard, <https://www.who.int/emergencies/diseases/novel-coronavirus-2019> (2020, accessed 13 June 2020).
2. Clinical features of patients infected with 2019 novel coronavirus in Wuhan, China Huang, Chaolin et al. *The Lancet*, Volume 395, Issue 10223, 497 – 506
3. Lieveveld AWE, Kok B, Schuit FH, et al. Diagnosing COVID-19 pneumonia in a pandemic setting: Lung Ultrasound versus CT (LUVCT) A multi-centre, prospective, observational study. *ERJ Open Res.* 2020;00539–2020. Published 2020 Oct 16. doi:10.1183/23120541.00539-2020a
4. Guan W, Ni Z, Hu Y, et al. Clinical characteristics of coronavirus disease 2019 in China. *N Engl J Med* 2020; 382: 1708—1720.
5. Wong HYF, Lam HYS, Fong AH, et al. Frequency and distribution of chest radiographic findings in COVID-19 positive patients. *RSNA*. Epub ahead of print 27 March 2020. DOI: 10.1148/radiol.2020201160.
6. Weinstock MB, Echenique A, Russell JW, et al. Chest X-ray findings in 636 ambulatory patients with COVID-19 presenting to an urgent care center: a normal chest X-ray is no guarantee. *J Urgent Care Med* 2020; 14: 13—18.
7. Trauer MM, Matthies A, Mani N, McDermott C, Jarman R. The utility of lung ultrasound in COVID-19: A systematic scoping review. *Ultrasound.* 2020;28(4):208–222. doi:10.1177/1742271X20950779
8. Lichtenstein DA and Meziere GA. Relevance of lung ultrasound in the diagnosis of acute respiratory failure: the BLUE protocol. *Chest* 2008; 134: 117—125.
9. Tsung JW, Kessler DO and Shah VP. Prospective application of clinician-performed lung ultrasonography during the 2009 H1N1 influenza A pandemic: distinguishing viral from bacterial pneumonia. *Crit Ultrasound J* 2012; 4: 16. 7.
10. Tsai NW, Ngai WC, Mok KL, et al. Lung ultrasound imaging in avian influenza A (H7N9) respiratory failure. *Crit Ultrasound J* 2014; 6: 6. 8.

11. Zhang YK, Li J, Yang J, et al. Lung ultrasonography for the diagnosis of 11 patients with acute respiratory distress syndrome due to bird flu H7N9 infection. *Virol J* 2015; 12: 176.
12. Smith, M.J., Hayward, S.A., Innes, S.M. and Miller, A.S.C. (2020), Point of care lung ultrasound in patients with COVID 19 — a narrative review. *Anaesthesia*, 75: 1096–1104. <https://doi.org/10.1111/anae.15082>.
13. Health Education England e-Learning for Health, Lung Ultrasound for COVID--19 e-Learning, <https://www.e-lfh.org.uk/programmes/lung-ultrasound-for-covid-19/> (2020, accessed 18 November 2020)
14. McDermott C, Daly J, Carley SCombating COVID-19: is ultrasound an important piece in the diagnostic puzzle? *Emergency Medicine Journal* 2020;37:644–649.

Author



Dr. Nick Mani, MD

@EveryoneNoOne1

BMedSci(1stHonsShef), BChB(Shef),
PgCSurgSci(Edin) PgCMedRes(Aberd),
PgCMedEd(Shef), PgCMedUS(Tees),
MRCS(Glasg), MRCEM(Lond)

Emergency Medicine Specialty Trainee
Year 5/6 and Senior Clinical Fellow in
PoCUS, Leeds Teaching Hospitals NHS Trust
Emergency Department, United Kingdom.

PoCUS Certified/Qualified

@TeesUnivPoCUS

@PoCUS_UK

@FEMUS_UK Founder/Chair

www.PoCUSUK.org